

Association between Histological Diagnosis and High-Risk HPV Genotyping Clinically Suspected Precancerous Lesions of Cervix

DOI: dx.doi.org



Jubyda Shahnur Rashid^{1*}, Papia Rahman², Rizwana Rahman Khan³, Syeda Sadia Afrin⁴, Nondita Mudi⁵, Mridul Kumar Saha⁶, Farida Yeasmin⁷, Saiyeda Sinthia Karim⁸, Rezaul Karim Dewan⁹

Received: 28 Jan 2024
Accepted: 4 Feb 2024
Published: 14 Nov 2024

Published by:
Sher-E-Bangla Medical College,
Barishal, Bangladesh

*Corresponding Author



This article is licensed under a
[Creative Commons Attribution 4.0
International License](https://creativecommons.org/licenses/by/4.0/).



ABSTRACT

Introduction: Cervical cancer remains a significant public health challenge, particularly in low- and middle-income countries (LMICs) with limited access to screening and vaccination programs. This study evaluates the association between high-risk HPV genotyping and histological diagnoses in clinically suspected cervical lesions in Bangladesh, focusing on precancerous conditions. **Methods & Materials:** A descriptive cross-sectional study was conducted on 51 women with clinically suspected cervical lesions. Cervical swabs were analyzed for high-risk HPV genotypes using RT-PCR, and histological diagnoses were categorized into precancerous (CIN I, CIN II, CIN III) and cancerous lesions. Cytological findings were assessed using the 2014 Bethesda system. Data were analyzed for associations between HPV genotypes, histological diagnoses, and cytological findings. **Results:** HPV 16 was the most prevalent genotype (41.18%), significantly associated with high-grade lesions such as CIN III (66.7%) and CIN II (33.3%). Nearly half of the cases (47.06%) were HPV-negative, predominantly in low-grade lesions like CIN I and NILM. Co-infections were rare (1.96%) and observed in severe lesions. The highest prevalence of high-grade lesions was seen in women aged 41–50 years. ASCUS was the most common cytological finding in CIN I (78.6%), while HSIL was most strongly associated with CIN II and CIN III. Significant associations were observed between HPV genotypes, histological diagnoses, and cytological findings ($p < 0.001$). **Conclusion:** This study underscores HPV 16's key role in cervical cancer and highlights the need for improved HPV genotyping, screening, and vaccination in Bangladesh.

Keywords: Cervical cancer, HPV genotyping, Precancerous lesions, Histological diagnosis, Bangladesh

(The Planet 2023; 7(2): 231-236)

1. Assistant Professor, Department of Pathology, Sir Salimullah Medical College, Dhaka, Bangladesh
2. Curator, Department of Pathology, Shaheed Suhrawardy Medical College, Dhaka, Bangladesh
3. Assistant Professor, Department of Pathology, Dhaka Medical College, Dhaka, Bangladesh
4. Lecturer, Department of Pathology, Dhaka Medical College, Dhaka, Bangladesh
5. Lecturer, Department of Pathology, Shaheed Suhrawardy Medical College, Dhaka, Bangladesh
6. Assistant Professor, Department of Pathology, Colonel Malek Medical College, Manikganj, Bangladesh
7. Associate Professor, Department of Pathology, Aichi Medical College, Dhaka, Bangladesh
8. Associate Professor (CC), Department of Pathology, Dhaka Medical College, Dhaka, Bangladesh
9. Professor and Head, Department of Pathology, Green Life Medical College, Dhaka, Bangladesh

INTRODUCTION

Cervical cancer remains one of the most significant global public health challenges, particularly affecting women in low- and middle-income countries (LMICs). Globally, cervical cancer ranks as the fourth most common cancer among women, with an estimated 604,000 new cases and 342,000 deaths reported annually [1]. However, the progression to cervical cancer is largely preventable with the identification and treatment of its precancerous lesions, namely cervical intraepithelial neoplasia (CIN). CIN is categorized into CIN I (low-grade squamous intraepithelial lesions) and CIN II and CIN III (high-grade squamous intraepithelial lesions), based on histopathological findings [2]. In LMICs such as Bangladesh, the burden of cervical cancer can be traced to systemic challenges, including inadequate screening programs, limited healthcare access, and poor awareness of preventive measures such as HPV vaccination [3]. Persistent infection with high-risk human papillomavirus (HR-HPV) is a well-

established precursor to the development of CIN, with HPV16 and HPV18 being the most common genotypes associated with high-grade lesions and cancer [4]. Other HR-HPV genotypes, including HPV52 and HPV58, are also notable for their oncogenic potential, particularly in South and East Asia [5]. In Bangladesh, precancerous cervical lesions remain underdiagnosed due to a lack of widespread screening and molecular diagnostic tools, leading to delayed treatment and progression to invasive disease [6]. Regional studies have shown that HPV16 and HPV18 are the most prevalent genotypes, with others such as HPV58 and HPV52 also being frequently detected [7]. These findings underscore the importance of understanding the association between HPV genotypes and CIN for developing effective screening and prevention strategies. Histological evaluation remains the gold standard for diagnosing CIN and determining its severity. Integrating histology with HPV genotyping enhances diagnostic accuracy by identifying individuals at high risk of

lesion progression [8]. For example, HPV16-associated lesions are known to progress more rapidly to CIN III compared to lesions associated with other genotypes [9]. Additionally, genotyping facilitates the detection of co-infections, which may influence lesion progression, and informs vaccination strategies by identifying the most prevalent genotypes in the region [10]. Despite these advances, there is limited data on the prevalence and distribution of high-risk HPV genotypes among Bangladeshi women with precancerous lesions, creating an unmet need for region-specific research. This study aims to evaluate the association between histological diagnoses and high-risk HPV genotypes in clinically suspected precancerous cervical lesions in Bangladesh. By providing insights into genotype-specific risks and lesion severity, this research seeks to guide public health policies, optimize screening protocols, and improve clinical outcomes for Bangladeshi women.

METHODS & MATERIALS

This study was a descriptive cross-sectional analysis conducted at the Department of Pathology, Dhaka Medical College, in collaboration with DNA Solution Ltd., a diagnostics and research laboratory, between July 2018 and June 2020. A total of 51 women, aged 25–60 years, were enrolled based on specific inclusion criteria: patients with a positive Visual Inspection with Acetic Acid (VIA) test, those with clinically suspicious cervical lesions requiring biopsy, and individuals attending the Gynecology Outpatient Department of Dhaka Medical College Hospital. Cervical samples were collected using a standardized procedure. Cervical swabs were taken for high-risk human papillomavirus (HR-HPV) genotyping via Real-Time Polymerase Chain Reaction (RT-PCR), targeting genotypes 16, 18, and other high-risk variants (e.g., 31, 33, 51, 52, 58). Histological sections were prepared from colposcopy-guided cervical biopsies and stained with hematoxylin and eosin (H&E) for histopathological analysis. Initial analysis included all 51 patients to assess baseline characteristics and HPV genotype distribution across the study population. Based on histopathological findings, lesions were classified into precancerous categories (CIN I, CIN II, CIN III) and cancerous lesions (invasive squamous cell carcinoma and adenocarcinoma). Further analysis, including the association between HR-HPV genotypes and histopathological diagnoses, focused solely on the subset of patients with precancerous lesions. Cytological examination was performed using Pap smear slides, which were stained and analyzed based on the 2014 Bethesda system. Cytological findings were categorized into Negative for Intraepithelial Lesions or Malignancy (NILM), Low-Grade Squamous Intraepithelial Lesion (LSIL), High-Grade Squamous Intraepithelial Lesion (HSIL), Atypical Squamous Cells of Undetermined Significance (ASCUS), and other relevant diagnoses. Data were analyzed using SPSS 22.0. Continuous variables were expressed as mean \pm standard deviation, and categorical variables as frequency and percentage. Initial comparisons of clinicopathological characteristics and HPV genotype distribution were

performed across all study participants. For the subset analysis focusing on precancerous lesions, associations between HR-HPV genotypes and histopathological categories (CIN I, CIN II, CIN III) were evaluated using the chi-square test, with a p-value <0.05 considered statistically significant.

RESULTS

Table – I: Age Distribution of Study Population

Age Group (Years)	Frequency (n=51)	Percentage (%)
21-30	9	17.7
31-40	14	27.6
41-50	19	37.4
51-60	9	17.7
Mean \pm SD	41.86 \pm 9.84	

The study population consisted of 51 women with a mean age of 41.86 years (\pm 9.84). The majority of participants (37.4%) were aged 41–50 years, followed by 27.6% in the 31–40-year age group. Equal proportions of participants (17.7% each) were observed in the 21–30 and 51–60-year age groups, indicating a diverse distribution across mid-to-late reproductive and post-reproductive age ranges.

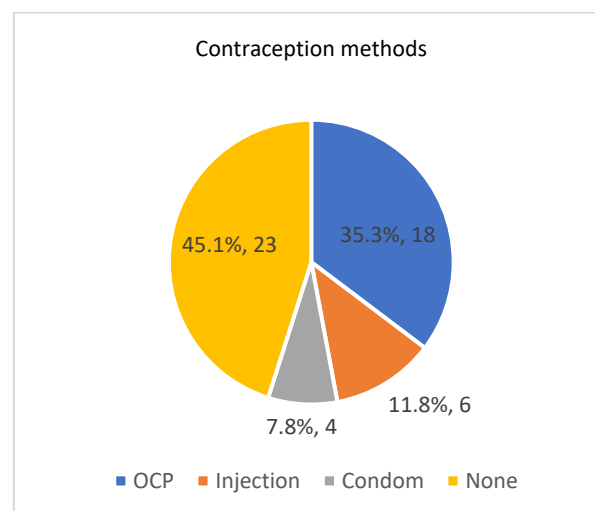


Figure – 1: Pie chart showing contraception method of the study patients

The contraception methods used by the study participants revealed that 45.1% of women did not use any contraception, making this the most common category. Among those using contraception, oral contraceptive pills (OCP) were the most prevalent method (35.3%), followed by injectable contraceptives (11.8%). Condom use was the least common, reported by 7.8% of the participants.

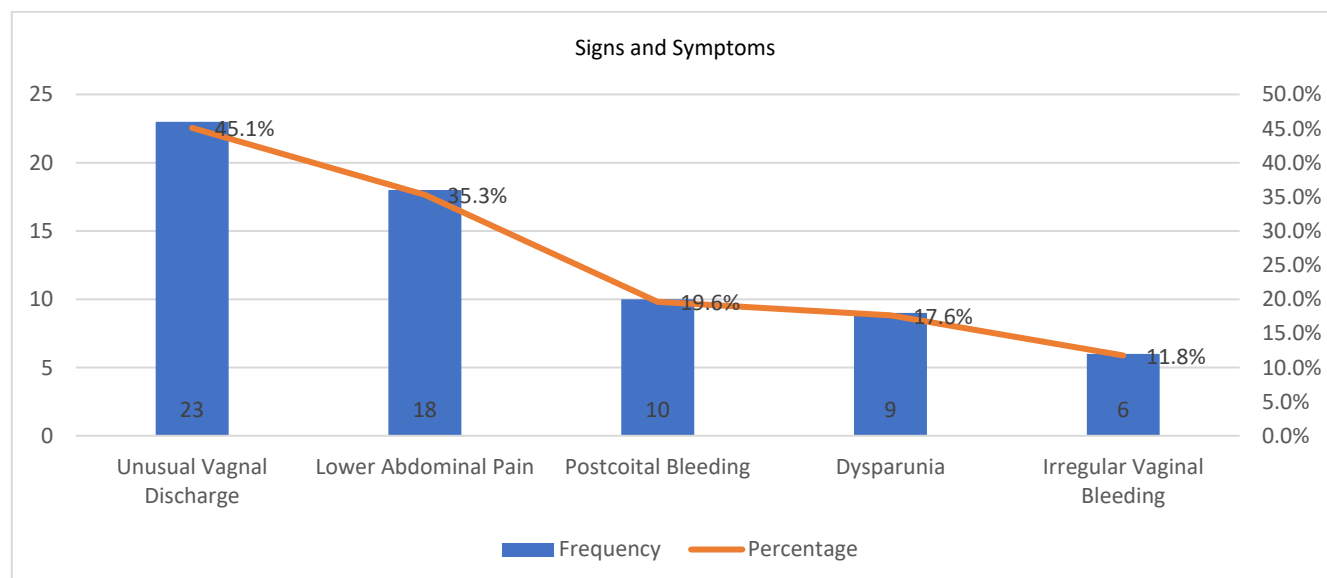


Figure – 2: Pie Chart Showing Signs and Symptoms of the Study Population

The most frequently reported symptom among the study population was unusual vaginal discharge, affecting 45.1% of participants. This was followed by lower abdominal pain, reported by 35.3% of women. Postcoital bleeding and dyspareunia (pain during intercourse) were observed in 19.6% and 17.6% of participants, respectively, while irregular vaginal bleeding was the least common symptom, reported by 11.8% of the women.

Table – II: High-Risk HPV Genotype Distribution

High-Risk HPV Genotype	Frequency (n=51)	Percentage (%)
HPV 16	21	41.18
HPV 18	3	5.88
HPV 68	1	1.96
HPV 16, 18 (co-infection)	1	1.96
HPV 16, 51 (co-infection)	1	1.96
HPV Not Identified	24	47.06

Among the study population, HPV 16 was the most prevalent high-risk genotype, identified in 41.18% of participants. HPV 18 was detected in 5.88% of cases, while HPV 68 accounted for 1.96%. Co-infections of HPV 16 with HPV 18 and HPV 51 were also observed, each comprising 1.96% of the population. Notably, no high-risk HPV genotype was identified in 47.06% of participants, indicating a significant proportion of HPV-negative cases in this cohort.

Table – III: Histological Diagnosis of the Study Population

Histological Diagnosis	Frequency (n=51)	Percentage (%)
CIN I (Low-Grade Squamous Lesion)	18	35.3

CIN II (High-Grade Squamous Lesion)	12	23.5
CIN III (Severe Dysplasia)	3	5.9
Cancerous Lesions	18	35.3

The histological diagnoses of the study population revealed that precancerous lesions were predominant, with CIN I (low-grade squamous lesion) being the most common diagnosis, accounting for 35.3% of cases. CIN II (high-grade squamous lesion) was observed in 23.5% of participants, while CIN III (severe dysplasia) was identified in 5.9%. Cancerous lesions also comprised a significant portion, representing 35.3% of the study population, highlighting the spectrum of cervical lesion severity within the cohort.

Table – IV: Cytological diagnosis of the pre-cancerous lesion patients (n=33)

Cytological Diagnosis	Frequency	Percentage (%)
NILM	3	9.1
ASCUS	13	39.4
LSIL	6	18.2
ASCH	4	12.1
HSIL	7	21.2

Among the 33 patients with precancerous lesions, cytological diagnoses revealed that atypical squamous cells of undetermined significance (ASCUS) were the most common, observed in 39.4% of cases. High-grade squamous intraepithelial lesions (HSIL) were identified in 21.2%, while low-grade squamous intraepithelial lesions (LSIL) accounted for 18.2%. Atypical squamous cells, cannot exclude high-grade squamous intraepithelial lesion (ASCH), were noted in 12.1% of cases, and Negative for Intraepithelial Lesions or Malignancy (NILM) was the least frequent diagnosis, observed in 9.1% of patients.

Table – V: Association between histological diagnosis and cytological findings among pre-cancerous lesions (n=33)

Histological diagnosis	Cytological findings										Total (n=33)	p value
	NILM (n=3)		ASCUS (n=13)		LSIL (n=6)		ASCH (n=4)		HSIL (n=7)			
	n	%	n	%	n	%	n	%	n	%		
CIN I	2	20.0	11	78.6	5	83.3	0	0.0	0	0.0	18	<0.001
CIN II	1	10.0	2	14.3	1	16.7	3	60.0	5	55.6	12	
CIN III	0	0.0	0	0.0	0	0.0	1	20.0	2	22.2	03	

The association between histological diagnosis and cytological findings among precancerous lesions showed significant trends ($p < 0.001$). CIN I was most commonly associated with ASCUS (78.6%) and LSIL (83.3%), while no cases of CIN I were linked to ASCH or HSIL. CIN II exhibited a broader

distribution, with HSIL being the most frequent cytological finding (55.6%), followed by ASCH (60.0%). CIN III was predominantly associated with higher-grade cytological findings, including ASCH (20.0%) and HSIL (22.2%), and had no association with NILM, ASCUS, or LSIL.

Table – VI: Association between Cytological Findings and High-Risk HPV Genotyping among pre-cancerous lesions (n=33)

Cytological Findings	HPV Not Identified	HPV 16	HPV 18	HPV 68	HPV 16, 18	16,51
NILM	2	1	0	0	0	0
ASCUS	8	7	0	0	0	0
LSIL	5	0	1	0	0	0
ASCH	2	1	0	1	0	1
HSIL	2	5	0	0	0	0

The association between cytological findings and high-risk HPV genotyping among precancerous lesions revealed notable trends. NILM cases were predominantly HPV-negative (2 cases), with one case associated with HPV 16. ASCUS had the highest proportion of HPV-negative cases (8), followed by HPV 16 in 7 cases. LSIL was primarily HPV-negative (5 cases), with one case linked to HPV 18. ASCH showed a diverse

profile, including HPV-negative (2 cases), HPV 16 (1 case), HPV 68 (1 case), and HPV 16/51 co-infection (1 case). HSIL was most frequently associated with HPV 16 (5 cases), with 2 cases being HPV-negative. These findings demonstrate a correlation between higher-grade cytological findings and the presence of HPV 16.

Table – VII: Association between Histological Diagnosis and High-Risk HPV Genotyping among pre-cancerous lesion cases (n=33)

Histological Diagnosis	HPV Not Identified	HPV 16	HPV 18	HPV 68	HPV 16, 18	Total
CIN I	9	8	1	0	0	18
CIN II	7	4	0	0	1	12
CIN III	1	2	0	0	0	3

The association between histological diagnosis and high-risk HPV genotyping among precancerous lesion cases revealed distinct patterns. Among CIN I cases, 50% were HPV-negative (9 cases), followed by HPV 16 detected in 44.4% (8 cases) and HPV 18 in 5.6% (1 case). For CIN II, 58.3% of cases were HPV-negative (7 cases), with HPV 16 identified in 33.3% (4 cases) and one case showing a co-infection with HPV 16 and 18. CIN III cases were predominantly associated with HPV 16 (66.7%, 2 cases), with only one HPV-negative case (33.3%). These results indicate that HPV 16 is the most prevalent genotype in higher-grade precancerous lesions.

DISCUSSION

Cervical cancer remains a significant global health challenge, particularly in low- and middle-income countries (LMICs) where limited access to screening and vaccination programs exacerbates the burden of disease. This study reinforces the critical role of high-risk HPV genotypes, particularly HPV 16, in the progression of cervical lesions. HPV 16 was the most

prevalent genotype in our study, significantly associated with high-grade lesions, including CIN III (66.7%) and CIN II (33.3%). These findings are consistent with studies by Guan et al. and Remmink et al., which reported escalating HPV 16 prevalence with lesion severity, from low-grade lesions like CIN I to high-grade lesions like CIN III and invasive carcinoma [11,12]. Interestingly, 50% of CIN I cases in this study were HPV-negative, a trend also observed by Sjoeborg et al., highlighting the heterogeneity in lesion etiology and emphasizing the importance of HPV genotyping for precise risk stratification [13]. Co-infections with HPV 16 and other high-risk genotypes, though rare in this study (1.96%), were noted in severe lesions like ASCH and CIN II. These findings align with Spinillo et al., who demonstrated that co-infections, particularly involving HPV 16 and HPV 18, are associated with an elevated risk of CIN III+ [14]. However, it remains clear from Guan et al. that single HPV 16 infections are the primary drivers of severe disease progression [11]. The distribution of lesion severity in this study showed the highest prevalence of high-grade lesions in the 41–50-year age group, consistent with findings

from Sjoeborg et al. and Yang et al., who attributed this trend to persistent HPV infections and the cumulative effects of viral oncogenesis [13,15]. These observations underscore the need for targeted screening efforts in middle-aged women to facilitate early detection and intervention. In terms of histological and cytological correlations, this study found ASCUS and LSIL predominantly associated with CIN I, while HSIL was most strongly linked to CIN II and CIN III. These findings mirror the work of Jahić and Balić, who reported significant concordance between cytology and histology in identifying high-grade lesions [16]. Furthermore, CIN I was identified as the most frequent low-grade lesion in our study (35.3%), a trend that aligns with global data reported by Zhao et al., reinforcing the utility of histological evaluation for accurate diagnosis and lesion grading [17]. The predominance of HPV 16 in high-grade lesions and its strong association with severe histological abnormalities emphasizes the critical importance of HPV-based screening and vaccination strategies. Studies by Guan et al. and Kelly et al. highlight that targeted vaccination programs, particularly addressing HPV 16, could significantly reduce the incidence of high-grade lesions and invasive carcinoma [11,18]. In conclusion, this study highlights the central role of HPV 16 in cervical carcinogenesis, particularly in driving the progression of high-grade lesions. It underscores the necessity of comprehensive genotyping to assess co-infections and their influence on lesion outcomes. Future research should prioritize elucidating the molecular mechanisms underpinning genotype interactions and their impact on lesion progression. Moreover, expanding screening and vaccination programs in resource-limited settings like Bangladesh remains imperative to mitigate the burden of cervical cancer and improve clinical outcomes for at-risk populations.

Limitations of The Study

The study was conducted in a single hospital with a small sample size. So, the results may not represent the whole community.

CONCLUSION

This study highlights the central role of HPV 16 in the progression of cervical lesions, particularly high-grade precancerous lesions like CIN III, and emphasizes its significant association with cytological abnormalities such as HSIL. The predominance of HPV-negative cases in low-grade lesions and the rarity of co-infections reinforce the heterogeneity of lesion etiology, underscoring the critical importance of HPV genotyping for risk stratification and targeted interventions. The findings align with global trends, particularly the association of persistent HPV 16 infections with lesion severity, while also providing region-specific insights into the age distribution and contraceptive use patterns among affected women. These results underscore the urgent need to strengthen HPV-based screening and vaccination programs, particularly in resource-limited settings like Bangladesh. Future research should focus on elucidating genotype interactions, enhancing early detection strategies, and optimizing public health interventions to reduce the cervical cancer burden in LMICs.

Funding: No funding sources

Conflict of interest: None declared

Ethical approval: The study was approved by the Institutional Ethics Committee

REFERENCES

1. Arbyn M, Weiderpass E, Bruni L, de Sanjosé S, Saraiya M, Ferlay J, et al. Estimates of incidence and mortality of cervical cancer in 2018: a worldwide analysis. *Lancet Glob Health*. 2020 Feb;8(2):e191–203.
2. Choi YJ, Lee A, Kim TJ, Jin HT, Seo YB, Park JS, et al. E2/E6 ratio and L1 immunoreactivity as biomarkers to determine HPV16-positive high-grade squamous intraepithelial lesions (CIN2 and 3) and cervical squamous cell carcinoma. *J Gynecol Oncol* [Internet]. 2018 May [cited 2024 Dec 18];29(3):e38. Available from: <https://www.ncbi.nlm.nih.gov/pmc/articles/PMC5920222/>
3. Torre LA, Islami F, Siegel RL, Ward EM, Jemal A. Global Cancer in Women: Burden and Trends. *Cancer Epidemiol Biomarkers Prev*. 2017 Apr;26(4):444–57.
4. Jentschke M, Soergel P, Hillemanns P. Importance of HPV Genotyping for the Screening, Therapy and Management of Cervical Neoplasias. *Geburtshilfe Frauenheilkd*. 2012 Jun;72(6):507–12.
5. Nahar Q, Sultana F, Alam A, Islam JY, Rahman M, Khatun F, et al. Genital Human Papillomavirus Infection among Women in Bangladesh: Findings from a Population-Based Survey. *PLOS ONE* [Internet]. 2014 Oct 1 [cited 2024 Dec 18];9(10):e107675. Available from: <https://journals.plos.org/plosone/article?id=10.1371/journal.pone.0107675>
6. Hoque MR, Haque E, Karim MR. Cervical cancer in low-income countries: A Bangladeshi perspective. *Int J Gynaecol Obstet*. 2021 Jan;152(1):19–25.
7. Jahan M, Islam T, Sultana S, Pervin M, Ashrafunnessa P, Tabassum S. Distribution of high risk Human Papilloma Virus genotypes among cervical cancer patients in a tertiary level hospital in Bangladesh: High risk Human Papilloma Virus genotypes. *Bangladesh Medical Research Council Bulletin* [Internet]. 2019 Aug 7 [cited 2024 Dec 18];45(2):86–92. Available from: <https://www.banglajol.info/index.php/BMRCB/article/view/42536>
8. Sideri M, Iqidbashian S, Boveri S, Radice D, Casadio C, Spolti N, et al. Age distribution of HPV genotypes in cervical intraepithelial neoplasia. *Gynecol Oncol*. 2011 Jun 1;121(3):510–3.
9. Castle PE. The potential utility of HPV genotyping in screening and clinical management. *J Natl Compr Canc Netw*. 2008 Jan;6(1):83–95.
10. Andersson S, Sowjanya P, Wangsa D, Hjerpe A, Johansson B, Auer G, et al. Detection of Genomic Amplification of the Human Telomerase Gene TERC, a Potential Marker for Triage of Women with HPV-Positive, Abnormal Pap Smears. *The American Journal of Pathology* [Internet]. 2009 Nov 1 [cited 2024 Dec 18];175(5):1831–47. Available from: [https://ajp.amjpathol.org/article/S0002-9440\(10\)60695-5/fulltext](https://ajp.amjpathol.org/article/S0002-9440(10)60695-5/fulltext)
11. Guan P, Howell-Jones R, Li N, Bruni L, de Sanjosé S, Franceschi S, et al. Human papillomavirus types in 115,789 HPV-positive women: a meta-analysis from cervical infection to cancer. *Int J Cancer*. 2012 Nov 15;131(10):2349–59.
12. Remmink AJ, Walboomers JM, Helmerhorst TJ, Voorhorst FJ, Rozendaal L, Risse EK, et al. The presence of persistent high-risk HPV genotypes in dysplastic cervical lesions is associated with progressive disease: natural history up to 36 months. *Int J Cancer*. 1995 May 4;61(3):306–11.
13. Sjoeborg KD, Tropé A, Lie AK, Jonassen CM, Steinbakk M, Hansen M, et al. HPV genotype distribution according to severity of cervical neoplasia. *Gynecol Oncol*. 2010 Jul;118(1):29–34.
14. Spinillo A, Dominoni M, Boschi AC, Soso C, Fiandrino G, Cesari S, et al. Clinical Significance of the Interaction between Human Papillomavirus (HPV) Type 16 and Other High-Risk Human Papillomaviruses in Women with Cervical Intraepithelial

- Neoplasia (CIN) and Invasive Cervical Cancer. J Oncol [Internet]. 2020 Oct 26 [cited 2024 Dec 18];2020:6508180. Available from: <https://www.ncbi.nlm.nih.gov/pmc/articles/PMC7648694/>*
15. Yang L, He Z, Huang X, Liu H, Tao J. Prevalence of human papillomavirus and the correlation of HPV infection with cervical disease in Weihai, China. *Eur J Gynaecol Oncol.* 2015;36(1):73–7.
 16. Jahic M, Balic A. Corelation between cytologic, colposcopic and pathohistological findings of cervical intraepithelial lesions. *Med Arh.* 2012;66(2):122–4.
 17. Zhao Y qian, Chang IJ, Zhao F hui, Hu S ying, Smith JS, Zhang X, et al. Distribution of cervical intraepithelial neoplasia on the cervix in Chinese women: pooled analysis of 19 population based screening studies. *BMC Cancer [Internet]. 2015 Jun 27 [cited 2024 Dec 24];15(1):485. Available from: <https://doi.org/10.1186/s12885-015-1494-4>*
 18. Kelly HA, Ngou J, Chikandiwa A, Sawadogo B, Gilham C, Omar T, et al. Associations of Human Papillomavirus (HPV) genotypes with high-grade cervical neoplasia (CIN2+) in a cohort of women living with HIV in Burkina Faso and South Africa. *PLoS One.* 2017;12(3):e0174117.